

PATIENT

Treacle Hildebrand

SPECIES

Feline

BREED

DMH

SEX

MN

AGE

15 y

WEIGHT

9.2 lb

INTERPRETED BY

Keith Blass, DVM, MS,
DACVIM (Cardiology)

IMAGING PERFORMED BY

Sonya Myers, DVM

HOSPITAL NAME

SonoFlo Mobile Vet.
Sonography of FL

REFERRING VET

Dr. Narayansingh

INVOICE

DATE

11/18/25

PRESENTING CLINICAL SIGNS

Grade 3/6 murmur. Abnormal SNAP BNP.

ECHOCARDIOGRAPHIC FINDINGS

2D, M-mode, and Doppler study.

Left atrial size is normal. The mitral valve appears normal, though mild mitral regurgitation is present. Left ventricular wall thickness is normal. Left ventricular internal dimensions are normal. Left ventricular systolic function is hyperdynamic. The aorta and aortic valve are normal. Right atrial and right ventricular dimensions are normal. The tricuspid valve appears normal, though trace tricuspid regurgitation is present. The pulmonary artery and pulmonic valve are normal. No shunting lesions are visualized. No pericardial effusion or cardiac masses are seen.

LA - 12.0 mm
LA/Ao - 1.09
IVSd - 5.3 mm
LVPWd - 4.5 mm
LVIDd - 11.9 mm
LVIDs - 3.9 mm
FS - 67%
RA - 10.5 mm
LVOT - 0.81 m/s
RVOT - 0.68 m/s

ASSESSMENT/RECOMMENDATIONS

This examination demonstrates mild regurgitation of blood across Treacle's mitral valve. The hemodynamic effects of the regurgitation also appear to be mild, as Treacle does not have secondary dilation of either of his left heart chambers. As such, Treacle's current risk for the development of congestive heart failure and/or thromboembolic disease appears to be low.

No therapy is recommended based on this exam.

A recheck echocardiogram is recommended in 9 months, sooner if new clinical signs compatible with cardiac dysfunction (ex. labored breathing, collapse, limb paralysis) develop.



PATIENT

Treacle Hildebrand

SPECIES

Feline

BREED

DMH

SEX

MN

AGE

15 y

WEIGHT

9.2 lb

INTERPRETED BY

Keith Blass, DVM, MS,
DACVIM (Cardiology)

IMAGING PERFORMED BY

Sonya Myers, DVM

HOSPITAL NAME

SonoFlo Mobile Vet.
Sonography of FL

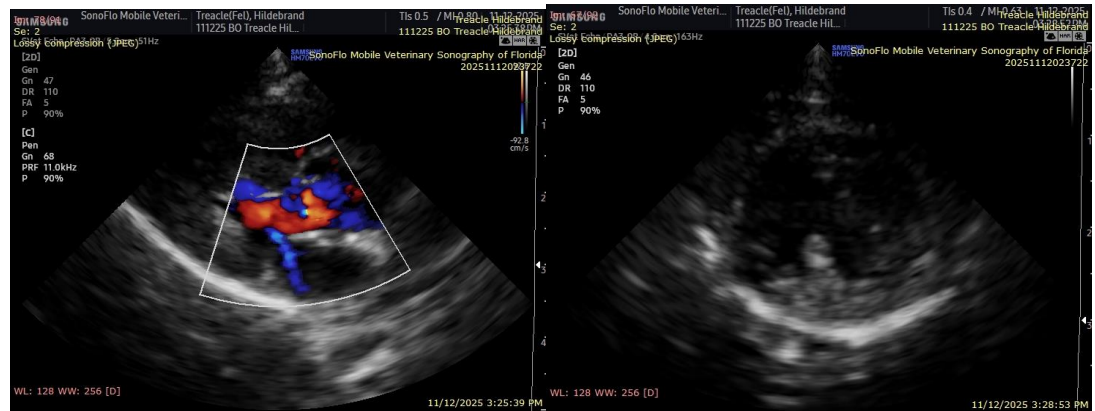
REFERRING VET

Dr. Narayansingh

INVOICE

DATE

11/18/25



The information and recommendations provided are based on the images presented by the referring veterinarian/sonographer. No evaluation can be communicated regarding pathology that was not visible in the image/video clips provided.

Thank you for this referral. If the clinical or image interpretation does not parallel your findings or if I can be of any further assistance please contact me.

Keith Blass, DVM, MS, DACVIM (Cardiology)

info@SonoPath.com